

See discussions, stats, and author profiles for this publication at: <https://www.researchgate.net/publication/320615919>

Vaginal Tightening Surgery: A New Technique

Article · November 2017

DOI: 10.21276/aimdr.2017.3.S1.10

CITATIONS

0

READS

5,383

3 authors, including:



Abdelmonem Awad Hegazy
Zagazig University

118 PUBLICATIONS 492 CITATIONS

[SEE PROFILE](#)

Some of the authors of this publication are also working on these related projects:



chemoprophylaxis of COVID-19 [View project](#)



Experimental study of effect of Formaldehyde on Rat Testis Structure [View project](#)

Vaginal Tightening Surgery: A New Technique.

Alaa Mohamed Edris¹, Abdelmonem Awad Hegazy², Waleed Mohamed Etman³

¹Consultant of General Surgery, Awlad Saqr Central Hospital, Ministry of Health, Zagazig 44519, Egypt.

²Consultant of Gynecology and Obstetrics & Chairman of Anatomy and Embryology Department, Faculty of Medicine, Zagazig University, Zagazig 44519, Egypt.

³Lecturer of Gynecology and Obstetrics, Faculty of Medicine, Zagazig University, Zagazig 44519, Egypt.

ABSTRACT

Background: There are many surgical and non-surgical procedures designed for tightening the lax or redundant vagina. However, these methods are still experimental with no satisfactory results. This study aimed to report a new simple technique through a traction of bulbocavernosus muscle (BCM) in a trial to satisfy both partners regarding the female cosmetic and sexual purposes. **Methods:** The procedure was conducted for ten women aged 25-35 years. After a good preoperative preparation, a small perineo-vaginal wall flap was done. Then, traction of BCM of both sides and their approximation using delicate stitches were performed without excision neither mucosa nor muscle neither skin. **Results:** The post-operative appearance of the perineum was good. Muscles' tone at the vaginal introitus had been improved. There was no detected fibrosis nor reported dyspareunia. The sexual pleasure for both partners was greatly increased by time starting after the first three months postoperatively for all cases. **Conclusions:** Simple plication of BCMs at the vaginal introitus could be suggested as a simple surgical method for tightening the redundant vagina. Future studies regarding large numbers of volunteers are recommended to accurately evaluate the results of such new technique.

Keywords: Vagina, Surgery, Tightening, Sexual pleasure, Bulbocavernosus.

INTRODUCTION

Female esthetic genital surgery to tighten a loose vagina has become very common nowadays.^[1] This type of surgery is performed to enhance the cosmetic appearance, size and function of the female external genitalia for satisfaction of both female and her sexual partner. Such procedures include vaginoplasty, vaginal rejuvenation, vaginal tightening, perineoplasty, clitoral hood reduction, labia majora augmentation, and G-spot amplification.^[2]

Vaginal tightening surgery has been documented in the mid-1950s; however, no standard procedure is found until now. Such procedures included an anterior and/or posterior colporrhaphy, excision of the lateral vaginal mucosa or a combination of the previous procedures to reduce the size or diameter of the vaginal canal aiming to do tightening the redundant or patulous vagina.^[2-4] All these techniques are derived from the classical gynecologic surgical repair applied to correct the pelvic floor defects, such as cystocele, rectocele and enterocele.^[3]

Name & Address of Corresponding Author

Dr. Abdelmonem Awad Hegazy,
Consultant of Gynecology and Obstetrics & Chairman of
Anatomy and Embryology Department,
Faculty of Medicine, Zagazig University,
Zagazig 44519, Egypt.

There are other non-surgical techniques such as local injections. However, these trials remain experimental. The implants mentioned in the literatures include autologous fat, the bulking agent, hyaluronic acid, and silicone.^[2,5,6] Such implants carry risk of death in some cases due to non-thrombotic pulmonary embolism (NTPE).^[7]

The vagina is surrounded and involved with skeletal pelvic floor muscles. This musculature includes BCM [Figure 1]. BCMs overlie the vestibular bulb to surround the vaginal introitus forming some sort of a sphincter.^[8]

BCM acts in females during sexual intercourse by stretch reflex. Sudden stretch of the muscle leads to its contraction.^[9] BCM is the pacemaker of pelvic floor muscles; its sudden stretch and contraction consequently lead to contraction of pelvic floor muscles.^[10]

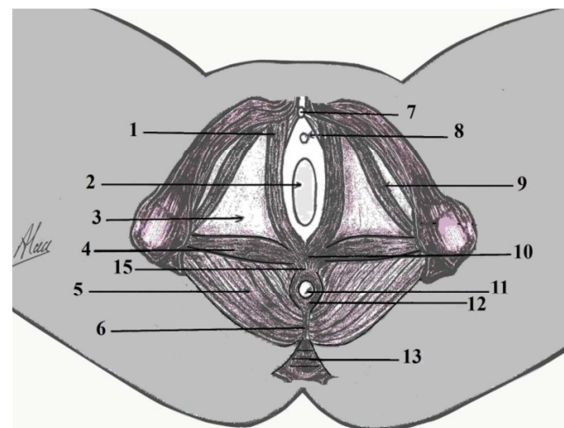


Figure 1: Anatomy of BCMs.

1-BCM. 2-Vagina. 3-Perineal membrane. 4-Superficial transverse perineal muscle. 5-Levator ani. 6-Anococcygeal body. 7- Clitoris. 8-Urethral orifice. 9-Ischio-cavernosus m. 10- Perineal body. 11- Anal orifice. 12- External anal sphincter m. 13- Coccyx.

Vaginal mucosa contains nerve plexuses, smooth muscle fibers and numerous blood vessels. During arousal phase, tumescence and elongation of vaginal lumen occurs, leading to narrowing vagina and more sexual pleasure due to fractional mucosal surface with the penis.^[11] Therefore, any vagino-plastic interference for sexual pleasure shouldn't neglect the role of BCM and vaginal mucosa. From this point

we present posterior vaginal wall flap and BCM traction. In this study, we aimed to report a new simple technique in order to tighten the patulous vagina. This method was a trial to enhance the female cosmetic and sexual functions through preservation of the two effective factors, namely the vagina mucosa and BCM.

METHODS

Subjects

The technique included ten women, aged 25-35 (mean: 33) years. The procedures were conducted in private hospital at Zagazig city the period from 2010-2012. The inclusion criteria were dysfunction sexuality (no sexual pleasure) and wide vaginal introitus (vaginal laxity or patulous vagina). The exclusion criteria patients were refuse of the technique and patients with previous history of vaginal operations or current vaginal infections, systemic diseases and pregnancy. Also, those with contraindications of operations such as bleeding tendencies were excluded. All operated females were consented.

Preoperatively

The operation was done 2 to 4 days after menstruation. The participant woman was given prophylactic treatment 250 mg (azithromycin dihyetrate /24 hours) for 3 days before the operation. The day before the operation, the patient had a low or non-residue diet; and adequate mechanical bowel evacuation was performed by a rectal enema 12 hours before the operation. Prophylactic antibiotic was carried out preoperatively using 1000 mg cefoperazone sodium IV given 2 hours before the operation. The perineal and genital area were shaved and cleaned with povidone iodine. Under general or spinal anesthesia, the patient was placed in lithotomy position. The gluteal, perineal genital and inguinal skin was painted with povidone iodine. The surgical field was dressed. The vaginal lumen was washed with normal saline.

Surgical steps

The anterior vaginal wall was elevated with a spatula. Bilateral labial traction was done with trans-fixation stitches at 4 and 8 O'clock to explore the vaginal fourchette (posterior commasure) to help in the exposure of the operative field. A V-shaped incision starting at the perineal body about 1.5-2.5 cm below the mucocoetaneous junction was done; and extended up to mucocoetaneous junction [Figure 2].

The lower skin flap was gently dissected for about 1-1.5 cm to mobilize the lower part of BCM; and the dissected area was backed with a small back soaked with normal saline. We were starting to dissect the upper perineal and vaginal mucosal flap upward for 2-2.5 cm [Figure 3]. Then, BCMs of both sides were identified and gently approximated and fixed by a

transverse inverted 0/3 vicryl stitches from down up for narrowing the vaginal introitus [Figures 4 & 5]. As a result of cooptation of tendons part of BCM, the size of the upper flap was becoming larger than the size of dissected area of posterior vaginal wall. It was managed with multiple placation stitches 0/5 vicryl to fixate the deep surface of the upper flap to the dissected surface of posterior vaginal wall. After that, we were starting to close the wound. The upper flap was approximated and stitched to lower flap with 0/3 vicryl stitches [Figure 6].

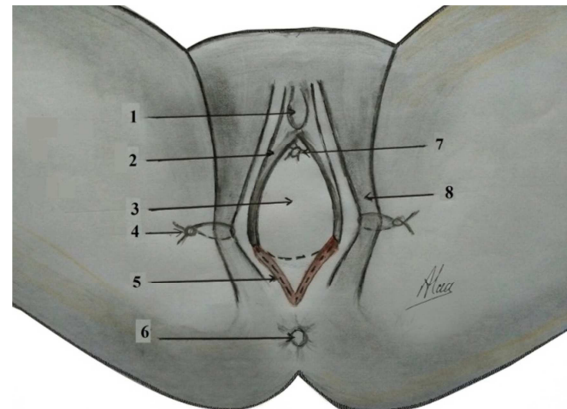


Figure 2: The first step of operation "V shape incision".
1-clitoris 2- labia minor 3-vaginal orifice 4- traction stitch 5- V shape incision 6-anus 7-urethral orifice 8-labia major.

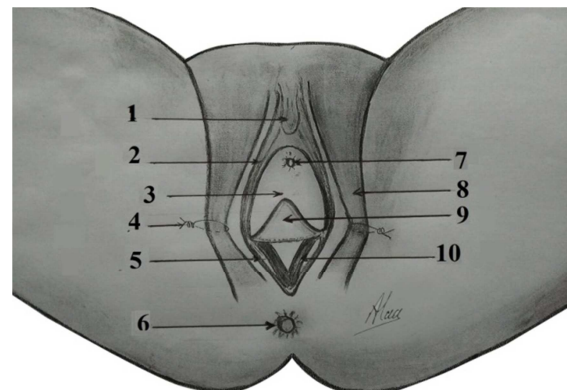


Figure 3: Elevation of the upper flap and exploration of BCM.
1- Clitoris. 2- Labia minor. 3- Vaginal orifice. 4- Traction stitch. 5- Lower flap. 6- Anus. 7- Urethral orifice. 8-Labia majora. 9-Upper flap. 10- BCM.

Post-operative care

The wound was painting with povidone iodine and we were packing the vagina with a small pack. The urethral catheter was removing after 3hours. Post-operative antibiotics 1000 mg cefoperazone sodium /12hs for 2 days was administered; followed by oral antibiotics and metronidazole for another 5 days. Analgesics were also given. The patient was resting in bed with intermittent movement and elevation of the legs. The vaginal pack was released at the next morning. The wound was painting with iodine. The patient was discharging from the hospital after 24 hours.

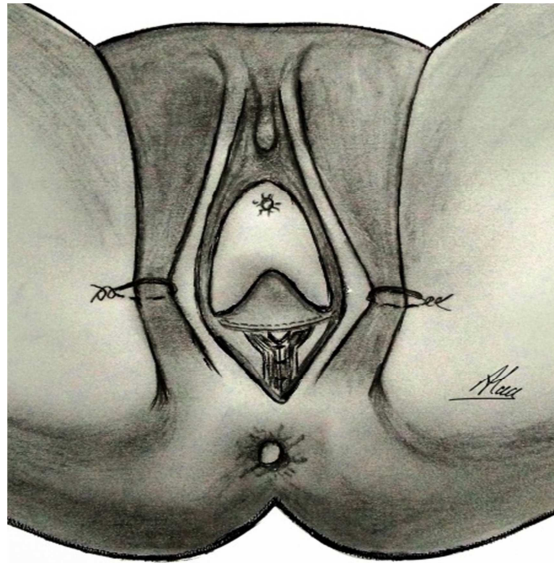


Figure 4: Closure of bulbocavernosus muscle.
1-clitoris 2-labia minor 3-vaginal orifice 4-traction 5-lower flab 6-anus 7-urethral orifice 8-labia major 9-upper flab 10-closed bulbocavernosus muscle.

vaginal examination. There was no reported dyspareunia. The sexual pleasure for both partners was greatly increased by time starting after the first three months postoperatively for all cases.

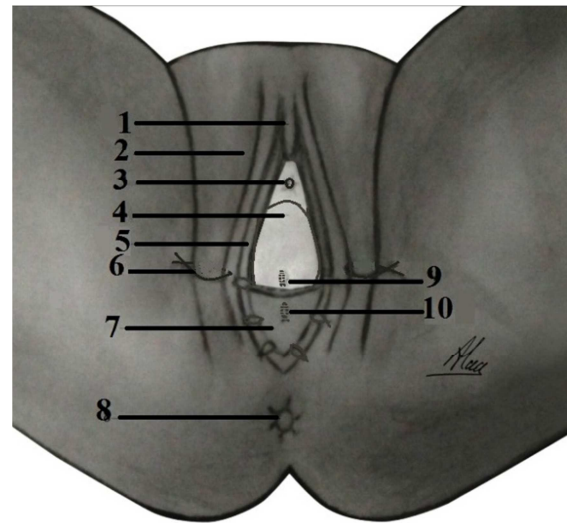


Figure 6: Last step of the operation and closure of the upper and lower flaps.
1-Clitoris. 2-Labia majora. 3-Urethral orifice. 4- Vaginal orifice. 5-Labia minora. 6- Traction stitch. 7-Upper flab. 8-Anus. 9-Mucosal plication stitch. 10-Skin fixation stitch.

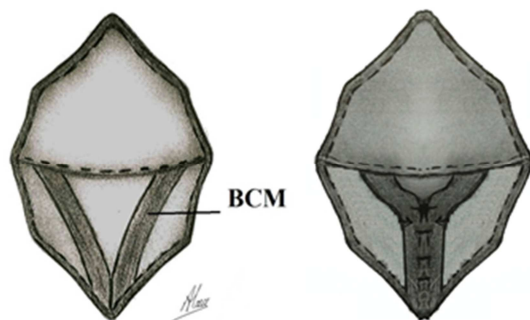


Figure 5: Diagrammatic figure for the operative area explaining the shape of BCMs before and after their approximation.

Follow-up

The patients were followed up for two years after the operation; at least one visit per month. They were instructed to abstain direct vaginal intercourse till at least two months after the operation. At their visits, they were checked for any complains and the status of their sexual life.

RESULTS

The results were satisfactory. The post-operative appearance of the perineum was good. Muscles' tone at the vaginal introitus had been improved in all cases as detected by palpation at vaginal examination. Moreover, the total surface area of vaginal mucosa was preserved. Only one case showed some wound infection; and treated with the appropriate antibiotic and anti-inflammatory medication. There was no detected fibrosis at

DISCUSSION

Any procedure for tightening the vagina for cosmetic or sexual pleasure and satisfaction without understanding the normal anatomical consistency and its physiological function does not reach the goal due to massive fibrosis and stiffness with rigidity (loss of elasticity contractions). The new technique respects the woman's rights in sexual pleasure. The technique was so simple; and the success rate was noticed in all cases involved. Sexual pleasure was satisfactory for both partners.

Sudden dilatation of the vagina leads to reflex constriction of BCM and pelvic floor muscles which render the vagina narrow.^[12] Therefore, any procedure for vaginal tightening with massive mucosal dissection and excision such as posterior colporrhaphy and bilateral mucosal excision runs against the goal of vaginal tightening due to massive fibrosis and rigidity of posterior vaginal mucosa which leads to reducing the blood supply of fibrosed mucosa. Disruption of pelvic autonomic plexus through massive dissection or excision of vaginal mucosa could result in difficulties and pain in sexual intercourse.^[13] Also, the destruction of nerve plexus by mucosal dissection and fibrosis will lead to reducing the mucosal sensation. This in turn will prevent the sexual pleasure and may cause painful sexual intercourse for female and leads to hypoactive sexual desire for female.^[14] Here, the dissection in the flab and BCM traction for patulous introitus of the vagina does not exceed one and half 1.5 cm of vaginal mucosa for mobilizing the tendons parts of

BCM and coapted together to close the introitus to become more sensitive to vaginal intercourse. BCM is a specific sexual pleasure muscle. On stretching the BCM with penetrating erected penis, the muscle reflexily contract and consequently the deep pelvic floor muscles contracts as a result of the contraction of BCM. So this muscle is considered the pacemaker pelvic floor muscles and is called the muscle of love.^[10,15] Moreover, BCM has an important role in the prevention of premature ejaculation. The penile erection is a vascular phenomenon. The penis is supplied by six different arteries; these vessels carry blood to erectile tissues which are present between the arteries and veins. The rate of arterial inflow is temporarily greater than the rate of veins outflow thus causing the characteristic increase in penile volume. Steady state is eventually reached when the rate of inflow equal to the rate of outflow and the penis ceases to enlarge but remains rigid. Reflexing contraction of BCM in female during intercourse helps to maintain the erection mechanically by obstructing the venous drainage.^[12] Rapid venous drainage causes impotence and premature ejaculation rendering the male partner to have a passive sexual need with insufficient sexual desire and lack of interest.^[16]

Vaginal mucosa is innervated with numerous blood vessels (highly vascular) and rich in nerve plexus. During sexuality, the mucosa is encouraged with blood, this will lead to tumescence of vaginal lumen and in turn increases the fractional surface which transmits the sensation through the nerve plexus, and this will lead to reflex contraction of pelvic floor muscle. This occurs as a result of the elasticity of the muscle whatever smooth or skeletal muscles.^[17] Therefore, any maneuver disturbs the normal anatomical and physiological function will be against the sexual pleasure. In posterior colporrhaphy, massive mucosal dissection and excision could disturb the vasculature, nerve plexus and elasticity of the muscles. Also, injection of autologous of fat tissues or hyaluronic acid (bulking agents) besides its complications during the injection, it reduces the vascularity' elasticity and nerve plexus through the stiffness of muscularis mucosa and pelvic floor muscles.^[18] In laser technique, the mechanism of action in vaginal tightening occurs through the shrinkage of mucosa and muscles.^[19] This will in turn be against the normal anatomical and physiological elasticity and contractility function; and will in turn change the vagina into rigid tube and deprives the woman from its right in sexual pleasure.

CONCLUSION

Simple plication of BCMs at the vaginal introitus could be suggested as a simple surgical method for tightening the redundant vagina. It gives satisfactory results regarding the cosmetic and sexual pleasure

for both partners. Further future studies regarding large numbers of volunteers are recommended to accurately evaluate the results of such new technique.

Acknowledgments

No external funding was provided. The authors declare that they have no conflict of interest. All participants were volunteers; and written consents were obtained from them. All the diagrams were done by the first author and revised and approved by the other two authors.

REFERENCES

1. Goodman MP. Female genital cosmetic and plastic surgery: a review. *J Sex Med.* 2011;8:1813–25.
2. Iglesias CB, Yurteri-Kaplan L, Alinsod R. Female genital cosmetic surgery: a review of techniques and outcomes, *Int Urogynecol J.* 2013;24:1997–2009.
3. Kent D, Pelosi MA. Vaginal rejuvenation: an in-depth look at the history and technical procedure. *Am J Cosmet Surg.* 2012;29:89–96.
4. Dobbeleir JM, Landuyt KV, Monstrey SJ. Aesthetic surgery of the female genitalia. *Semin Plast Surg.* 2011;25:130–41.
5. Park HJ, Jung KH, Kim SY, Lee JH, Jeong JY, Kim JH. Hyaluronic acid pulmonary embolism: a critical consequence of an illegal cosmetic vaginal procedure. *Thorax* 2010;65:360–1.
6. Bartsich S, Wu JK. Silicon emboli syndrome: a sequela of clandestine liquid silicone injections. A case report and review of the literature. *JPRAS* 2010;63:e1–e3.
7. Duan Y, Zhang L, Li S, Yi Yang, Xing J, Li W, Wang X, Zhou Y. Polyacrylamide hydrogel pulmonary embolism- A fatal consequence of an illegal cosmetic vaginal tightening procedure: A case report. *Forensic Sci Int.* 2014;238:e6–e10.
8. Shafik A, Mostafa RM, Shafik AA, El-Sibai O. Study of the effect of straining on the bulbocavernosus muscle with evidence of a straining-bulbocavernosus reflex and its clinical significance. *Int Urogynecol J Pelvic Floor Dysfunct.* 2002;13(5):294-8.
9. Jennifer R, Bassuk B. Physiological and path physiological female sexual function and dysfunction. *World J Urol* 2002;20:111-8.
10. Shafik A. Vaginocavernosus reflex. Clinical significance and role in sexual act. *Gynecol Obstet Invest.* 1993;35:114-7.
11. Ginger VAT, Yang CC. Functional anatomy of the female sexual organs. *Cancer and Sexual Health* 2011:13-23. Available at: https://link.springer.com/chapter/10.1007%2F978-1-60761-916-1_2
12. Shafik A, El Sibai O, Shafik AA, Ahmed I, Mostafa RM. The electrovaginogram: study of the vaginal electric activity and its role in the sexual act and disorders. *Arch Gynecol Obstet.* 2004;269(4):282-6.
13. Berman JR, Berman LA, Kanaly KA. Female Sexual Dysfunction: New Perspectives on Anatomy, Physiology, Evaluation and Treatment. *EAU Update Series.* 2003;1:166–77.
14. Berman L. Management of female sexual function. 2008; *Glob. libr. women's med.,* Berman, L, *Glob. libr. women's med.,* (ISSN: 1756-2228) 2008; DOI 10.3843/GLOWM.10433
15. Siegel AJ. Female pelvic relaxation. An educational service provided by Bergen Urological Associates. Hackensack University Medical Center Plaza. 2010;1-21. Available at:[http://pelvicrelaxation.com/Female_Pelvic_Relaxation_BK LT_10v3.pdf](http://pelvicrelaxation.com/Female_Pelvic_Relaxation_BK_LT_10v3.pdf)

16. AlNomair N, Nazarian R, Marmus E. Complications in Lasers, Lights, and Radiofrequency Devices. *Facial Plast Surg* 2012;28:340–6.
17. Ginger VAT, Yang CC. Functional anatomy of the female sexual organs. *Cancer and sexual health*. 2011. Available at:file:///C:/Users/target/Downloads/9781607619154-c1%20(1).pdf
18. Julce M, Dobbeleir LCL, Koenraad Van Landynyt MD, Monstery ST. *Aesthetic Surgery of Female Genitalia* 2011;25(2):130-41.
19. Jorge E, Gariria PA, Lanz I. Laser Vaginal Tightening (LVT) – evaluation of a novel noninvasive laser treatment for vaginal relaxation syndrome. *J Laser health Acad*. 2012;1:59-66.

How to cite this article: Edris AM, Hegazy AA, Etman WM. Vaginal Tightening Surgery: A New Technique. *Ann. Int. Med. Den. Res.* 2017;3(S1):32-36.

Source of Support: Nil, **Conflict of Interest:** None declared